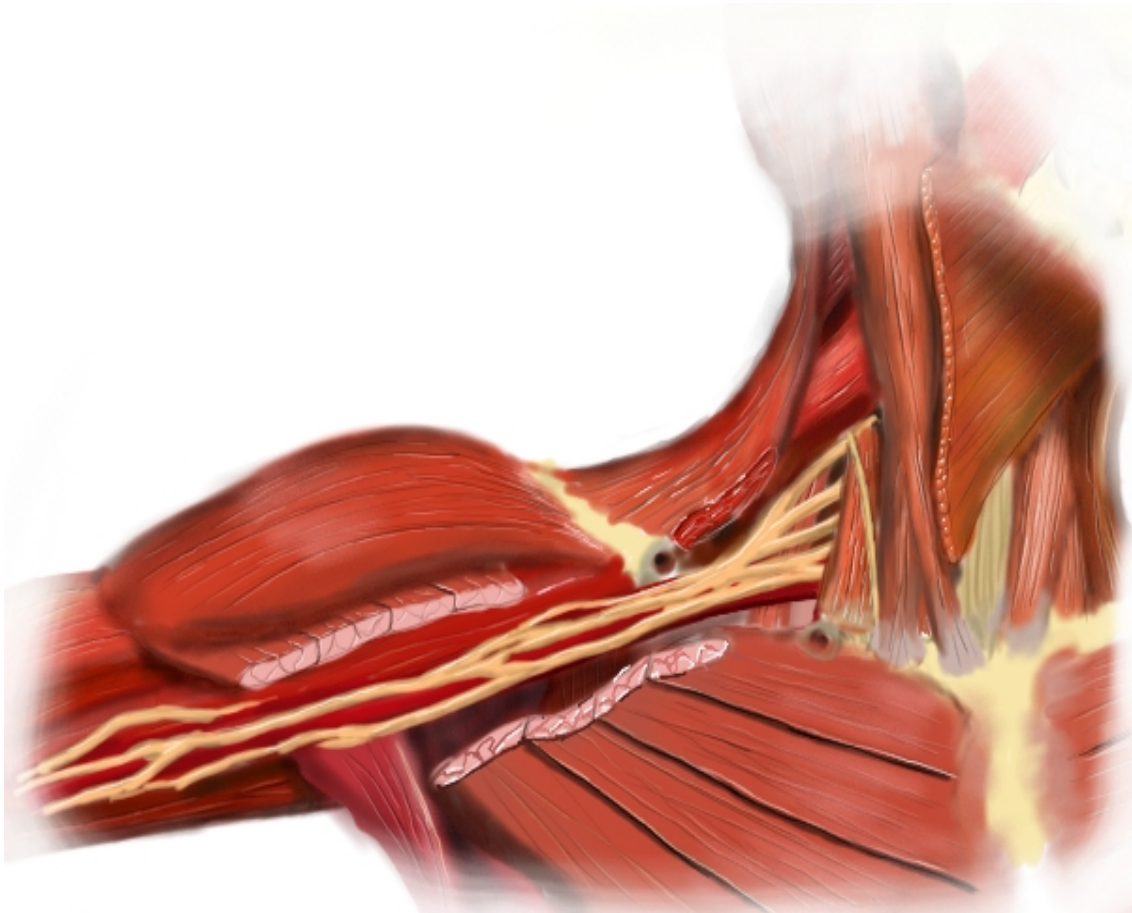


The Neuraxiom Playbook of 9 Essential Blocks

A Handbook of Ultrasound Guided Regional
Nerve Blocks

by Jack Vander Beek



I am a Registered Nurse with more than 30 years of experience assisting with anesthesia procedures. I became interested in the clinical uses of ultrasound for anesthesia several years ago and have taken a special interest (obsession) with the use of ultrasound for guiding the placement of regional block needles.

I've had a fascination with anatomy and physiology since I first read the entire Gray's Anatomy in high school. I started working with microcomputers since 1982 and with the internet since 1992. I've tried to use this broad mix of interests to present what I hope is a very simple and accessible format for learning and practicing the techniques of 9 of the most practical blocks for everyday clinical use.

I hope this effort is of use to you.

Thanks,

JACK VANDER BEEK



The Neuraxiom Playbook of 9 Essential Blocks

A Handbook of Ultrasound Guided
Regional Nerve Blocks

by Jack Vander Beek

Author & Publisher: Jack Vander Beek

Every effort has been made to confirm the accuracy of the information contained within this work. The author cannot be held responsible for errors or for any consequences arising from the use of the information contained herein, and makes no warranty, expressed or implied, with respect to the contents of this publication.

Printed in the United States

Permissions for Reprints should be addressed to Jack Vander Beek
at the email address jack@neuraxiom.com

Copyright © 2009 by Neuraxiom LLC
First Edition

All rights reserved.

No part of this book shall be reproduced, stored in a retrieval system,
or transmitted by any means without written permission from the author.

International Standard Book Number: 978-0-615-28289-3
Library of Congress Control Number: 2009926561

I would like to thank my friends, the anesthesiologists of Olympia Anesthesia Associates, for their unfailing support in helping me collect and create the techniques and content for this work.

Thanks also to those members of the same group who were patient enough to proofread and edit my endless ramblings into a much more readable set of ramblings.

The Playbook Table of Contents

The Disclaimer.....	xi
The Introduction.....	4
Survey Says	7
Where real life conflicts with technical writing.....	7
Ultrasound – The Real Story.....	10
The Plane, The Plane – The Plane of the Probe.....	11
The Scan Line.....	11
The Ultrasound Machine.....	14
The Advantages of Ultrasound Guidance.....	18
Getting Started with Ultrasound	24
Arm yourself with information and Enjoy the Guide.....	24
Step 1. Just Look.....	24
Step 2. Look After Your Old Block	25
Step 3. Watch Your Stimulator Block.....	25
Step 4. Time for Your Solo.....	25
Needling.....	26
Regional Block Needles and Approaches	30
Ultrasound Probe Orientation to the Nerve	31
The Short Axis View.....	31
The Long Axis View.....	32
Needle Orientation to Probe	33
Continuous Catheter Techniques.....	38
Materials.....	39
Serving Suggestions.....	39
Procedure.....	40
Tunnel the catheter.....	41
Test Injection.....	42
Dressing.....	42
Medications – (What Do I Know?).....	46
How blocks work: a conventional model.....	47
Exercising the Local Anesthetic Choices You Have.....	48
Bupivacaine.....	49
Ropivacaine.....	49
Making Blocks Last Longer.....	50
Epinephrine.....	50

Clonidine.....	51
Cooling of Injection Site.....	51
Adding Sodium Bicarbonate to Local Solution to Speed Onset.....	52
Local Anesthetic Toxicity and Lipid Rescue.....	52
Tips for Effective Ultrasound Blocks.....	56
The Interscalene Block.....	64
General Overview.....	64
Supplies & Materials.....	64
Patient Position.....	65
Survey Technique.....	65
Image Interpretation.....	66
Needle Approach.....	67
Miscellaneous.....	68
The Supraclavicular Block.....	74
General Overview.....	74
Supplies & Materials.....	75
Patient Position.....	75
Survey Technique.....	76
Image Interpretation.....	76
Needle Approach.....	77
Miscellaneous.....	79
The Axillary Block.....	86
General Overview.....	86
Supplies & Materials.....	86
Patient Position.....	86
Survey Technique.....	87
Image Interpretation.....	87
Needle Approach.....	88
Miscellaneous.....	89
The Fascia Iliaca Compartment Block.....	94
General Overview.....	94
Converting the Fascia Iliaca Block to a Continuous Catheter Block.....	95
Anatomy of the Fascia Iliaca Block.....	96
Key Points of the Fascia Iliaca Block.....	97
Supplies & Materials.....	99
Patient Position.....	99
Survey Technique.....	100
Image Interpretation.....	100
Needle Approach.....	101

Miscellaneous.....	103
The Femoral Block.....	108
General Overview.....	108
The Block Goeth before a Fall.....	108
Supplies & Materials.....	111
Patient Position.....	111
Survey Technique.....	112
Image Interpretation.....	113
Needle Approach.....	113
Miscellaneous.....	115
The Saphenous Block.....	120
General Overview.....	120
Supplies & Materials.....	123
Patient Position.....	123
Survey Technique.....	124
Image Interpretation.....	124
Needle Approach.....	125
Miscellaneous.....	126
The Neuraxiom Anterior Sciatic Block.....	134
General Overview.....	134
Ultrasound Visibility and Technique Workarounds.....	135
“Flashing the Adductor Magnus” to Find the Plane of the Sciatic.....	136
When You Can't See the Adductor Magnus Twitch.....	137
When the Adductor Magnus Muscle doesn't Twitch.....	137
Supplies & Materials.....	138
Patient Position.....	139
Survey Technique.....	139
Image Interpretation.....	140
Needle Approach.....	141
Miscellaneous.....	144
The Neuraxiom Posterior Sciatic Block.....	150
General Overview.....	150
Ultrasound Visibility and Technique Workarounds.....	151
Alternative 1 – Finding the Hamstrings.....	151
Alternative 2 – “Flashing” the Gluteus Maximus.....	152
Missed the Flashing Glutes?.....	152
Supplies & Materials.....	153
Patient Position.....	153
Survey Technique.....	154

Image Interpretation.....	155
Needle Approach.....	156
Miscellaneous.....	158
The Popliteal Sciatic Block.....	164
General Overview.....	164
Supplies & Materials.....	166
Patient Position.....	166
Survey Technique.....	167
Image Interpretation.....	168
Needle Approach.....	169
Miscellaneous.....	170
The Neuraxiom Illustration Index.....	175
Neuraxiom Playbook Index.....	177

The Disclaimer

Every good medical technique guide starts with “the disclaimer” and here is my version of this indispensable component. It's not that I don't want you to take the contents of this book seriously or that I think the ideas presented here aren't valuable and safe. But because what we are considering here is nothing less than working on real people I have to make sure that you are using all of your best training and technique along with the advice covered here.

I'm not there with you so I'm not in a position to grab your hand at that fateful moment, or throw myself between you and the ultrasound screen to remedy some procedural error that can result in unhappiness, so I'm going to craft this disclaimer carefully to point out that when it comes to sticking a needle into some other person you're the expert, not me.

I have tried to be accurate in my descriptions, my drawings, my procedures, my diagrams, and my advice, but this is a book, and I'm not standing next to you so I don't see what you see. Think of the contents of this book as the advice I would give you if I were standing next to you. The advice either should or shouldn't be taken into consideration, based on your evaluation of its worth in a given situation.

Nothing that I say or imply in this book should supersede the clinical judgment and acumen of the practitioner standing beside the patient – You.

The Neuraxiom Playbook is intended for use by medical professionals, specifically those who perform invasive regional anesthetic procedures. If you're reading this and don't know what I mean, you've bought the wrong book and you should return it to where you bought it for a full refund.

By now you should be aware that not everything you hear and read is true, real or appropriate to real life. So the following disclaimer is there for the obvious reasons. The short form is: ***IF IT DOESN'T MAKE SENSE OR SEEM RIGHT TO YOU, DON'T DO IT.*** Having said all of this I hope that the information found in this book is helpful to you in making decisions regarding your practice. Most of the techniques described here are either new and non-invasive (like ultrasound surveys) or invasive things you already do (like sticking needles into people).

So –

Neuraxiom LLC, myself and those people associated with it make no warranties as to the correctness, safety or appropriateness of any therapies, medications, dosages, techniques or any other aspects of medical practice or patient care and safety. Nothing in this book should be interpreted to imply that anything but YOUR BEST MEDICAL JUDGMENT is appropriate for making safe medical decisions and implementing therapies for your patients.

The Neuraxiom Playbook of 9 Essential Blocks

Chapter 1

Introduction

Let's Get This Started

neuraxiom.com

Ultrasound Guided Regional Nerve Blocks

The Introduction

You can't have a book without an introduction, so here goes. Why Neuraxiom? Actually, the name was supposed to be a combination of the root “neur” for nerve and “axiom” meaning “self-evident truth” because it favors the empirical product. It is kind of a coincidence that it sounds like “neuraxial”, which happens to point in the opposite direction from the peripheral nerves, and it's even more unintended that it sounds like “Neuraxis”, which is also a heavy metal band.

As I said, the appeal to me is the second part, “axiom”. A “self-evident truth”. This defines my approach to the field of ultrasound guided peripheral nerve blocks. This approach is based primarily on practical, useful, commonly-observed causes and effects of safely creating peripheral nerve blocks.

So, for the purposes of designing blocks, I have relied mostly on what I have observed. This means that if you are looking for a lot of footnotes and bibliography in this work, you're going to be somewhat disappointed. I do review references and literature, but I try to combine the information from these sources in ways that simplify the concepts and structures that are necessary components for the block.

Above all, I believe that the “Ultrasound Guidance” portion of the techniques we will cover is a beautifully pure form of applied anatomy, made even more exciting because the application advances the very worthwhile goals of relieving others of their pain.

I have tried to approach these techniques without pre-conceived notions about the way things are supposed to work and to look instead for experiences to inform me as to what to expect.

For instance, if you look in a book detailing the common characteristics of the different local anesthetics, you will find tables showing that bupivacaine has an onset time of 30 to 40 minutes. I don't know what to make of that because I've seen bupivacaine blocks that have taken hours to complete. One example of this involved a young man who had an interscalene brachial plexus block for shoulder repair. He had good coverage of the shoulder from the

block. He could move his fingers and grip his affected hand immediately after the block, and following the surgery, which took a little over an hour. Later, after leaving the recovery room and before discharge, his hand and fingers became involved in the block as well. (The block wore off in reverse order later the following day.)

I also know that the duration of effects from different local anesthetics are widely variable and have as much to do with the size of the nerve as the concentration and volume of the drug. For example, 30 mls of Bupivacaine 0.5% injected around the brachial plexus nerves may produce a block lasting anywhere from 16 – 28 hours, but the same 30 mls around the sub-gluteal sciatic nerve can produce a block lasting 48 – 72 hours.

I am always looking for a simple model for the actions of local anesthetics that fits all of the observations. I believe this may lead to an alternate working model of what can go wrong with nerve blocks and what can cause symptoms of nerve injury following otherwise unremarkable nerve blocks. If some of what I write seems “out of step” or unconventional or even (hopefully) overly simplistic, please humor me and my approach and read on.

My only goal is to present simple, safe, and effective procedures for performing a few of the most useful regional nerve blocks in a manner that is easy to understand, applicable to the greatest range of situations in patients, and successful in the greatest percentage of attempts.

As an aside, I have been asked what business I have advocating block methods to anesthetists. You probably know by now that I am not an anesthesiologist. I settled this matter in my mind quite some time ago. For many years, I assisted anesthesiologists with their regional blocks. In that time, I met many fine and generally skillful anesthesiologists who could handle almost any situation they found themselves in. Nevertheless, I also noticed that many of them could have blind spots in their practice when it came to regional nerve blocks. It seemed to me, like many other skills, they had learned one way to perform a block, sometimes many years earlier, and by default they clung to that method, whether it was successful or not.

The turning point in my thinking came one day years ago, when one of the senior anesthesiologists I worked with – I'll call him Dr. "A", a wonderful man and physician, who had been practicing anesthesia for over 30 years -- spoke to me privately asking if I had seen a better way of doing an axillary brachial plexus block than the method he had. Dr. "A" told me that, for his entire career, he had been performing axillary blocks and he had never been satisfied with the method. Some of his blocks worked and some of his blocks didn't, and he didn't know why. I had the feeling from our conversation that he had almost come to dread those occasions when it was necessary for him to perform an axillary brachial plexus block. I told him about the method I had seen used by one of his colleagues (Dr. "B") that seemed to work the majority of the time. From that time on, Dr. "A" used the Dr. "B" method for his axillary blocks (Are you still following me?) with successful results.

A few years later, when our department purchased our first ultrasound machine, we primarily used it for central venous access, but I began experimenting with it to identify nerves. After I had successfully mapped out the location of the nerves of the brachial plexus in the axilla, I approached Dr "B", whose method for axillary block I had related to Dr. "A" (now retired). I explained my methods for ultrasound guidance of the needle to the nerves for the axillary block to Dr. "B" and asked him if he would be interested in trying it out. I remind you here that this is the very anesthesiologist whose method I had considered the most successful and easily explainable to someone who needed help. Upon hearing my proposal this fellow was immediately eager to try it, and after a few times of using ultrasound guidance for placing the needle next to the nerves he dropped his previous method (which was the trans-arterial method) and never used it again.

While this was something of a success story for me, it was a greater success story for Dr. "B" because he had just acquired a method that made more sense to him and had more consistent results. It took the guesswork out of the block.

I also work with anesthesiologists who just seem to have the perfect touch for nerve blocks as they have demonstrated over the years. Unerringly, they find the brachial plexus in the interscalene space or the axillary space with nerve stimulators. They seem to have x-ray

vision when it comes to performing a femoral or sciatic block with stimulators. Even though they really did not need to necessarily embrace the ultrasound technology, most of them have. I cannot explain how these gifted individuals could find their target nerves with as few needle passes as it usually took, but I can explain how to find those targets with as few or fewer passes with ultrasound, and therein lies the difference. Ultrasound technology levels the playing field for all of those people who don't have a preternatural knack for nerve blocks. Ultrasound guidance can place those high success rates, and I think, lower complication rates in your hands.

Regional nerve blocks are part of every anesthetist's practice. Almost everyone who gives anesthesia is expected to be able to perform regional nerve blocks in some cases as the anesthetic and in other cases for postoperative analgesia. Whether they have the skills, whether they have some sort of natural talent, anesthetists will be sticking needles into patients, sometimes over and over. My motivation is to keep the number of needle passes to a minimum, keep the level of safety at a maximum, and to bring the success rate to as near perfect as possible. Creating methods for safe and effective blocks benefits everyone, most importantly the patient.

Survey Says ...

I use the word, “**Survey**”, frequently in this work. Sometimes as a noun and sometimes as a verb. Probably too much. The noun form means the *ultrasound image* you create using the probe, the gel, and the rest of the gear. The verb Survey means the *technique* or *plan* you are using to find the target.

Where real life conflicts with technical writing.

Many of you know that before writing this I had created a website, <http://neuraxiom.com>. Working with this website taught me a great deal about long distance teaching and even more about how I wanted to do it. Let me explain that if you want to make a website that is useful and understandable, and it involves ultrasound images, at some point you have to decide which pictures to put on the site. This is a common problem with anyone making a site with ultrasound images.

There are basically 3 kinds of images that you have to choose from when you're creating a chapter on ultrasound image interpretation. The first kind is crisp and clear, with plenty of detail, showing layers, boundaries and all the anatomical structures toward which you intend to direct the visitors' attention. The second type of image could be called equivocal, it shows less distinct definition of boundaries in layers and the anatomical structures are not as well defined. The third type of image seen on ultrasound survey could be called "not ideal", crummy, or even featureless. All three of these types are very common when you are performing ultrasound surveys. But guess which type is the most common to both our website or in books about ultrasound surveys? That's right, type 1 the perfect image. This is necessary so that the reader or visitor can see what you're talking about. The nice pictures allow you to put arrows, circles, and notes that aid in meaningful interpretation of the picture. These pictures also can lead the new visitor or reader to believe that this is the type of image that they should expect to see on every ultrasound survey they perform. And when they don't see the characteristic image they feel like there's something wrong with them, or with their equipment, or with their technique. This is not the case. As we discuss later under Chapter 2, "Ultrasound, The Real Story", you can see good detail on most people, but on some people, inexplicably (at least to me, right now), the ultrasound survey is foggy and lacks definition. This does not seem to be related to body habitus, age, or general condition. I think it may relate to hydration. I'll get back to you when I figure it out.

The techniques we will talk about here are meant to be used with almost any quality ultrasound image. Unless your practice is limited to performers from Cirque du Soleil, I don't expect your patients to provide you with picture-perfect images to help guide your needle. Therefore, there will be tips along the way for dealing with less than perfect images. This is, after all, real-life.